



The practice of illegally killing big game animals with a firearm during an archery season is widespread. An arrow is often inserted into the bullet wound to make the wound appear as an arrow wound and the game is then tagged with an archery tag. Keeping in mind that arrows “cut” and bullets “crush”, it is usually not too difficult to differentiate a true arrow kill from a staged arrow kill. The violator may think he has gotten away with his deception once he has his trophy hanging in camp or even at the meat processor. However, the astute investigator may still tag the violator with a citation. The objective of this article is to provide the field investigator with a set of observations which may assist in the documentation and eventual prosecution of this common wildlife violation.

Arrow verses Gunshot

TIPS FOR FIELD INVESTIGATORS

Mechanism of Wounding

Most bullets, even from pistols and .22 rim fire rifles travel at velocities 750 to 3500 fps (foot per second). Arrows travel at velocities of around 300 fps. Arrows are designed to cut vital organs and do not tend to crush or tear tissues like a bullet along the wound tract. Therefore, arrow wounds are fundamentally different from a pathological point of view, than bullet wounds. This fact should be kept in mind while examining carcasses which are claimed to be archery killed animals.

As a bullet enters the tissue of an animal, kinetic energy, a product of mass and velocity of the bullet, is lost into the tissue. As the bullet slows, which is further enhanced by mushrooming of the bullet, energy is dispersed around the wound path of the

projectile causing tissue expansion and disruption at the microscopic level along with actual crushing of tissue by the bullet itself (See Figure 1). The higher the velocity and/or mass of the projectile, the greater the energy, and the more potential for radiating damage. The fragmentation of the bullet associated with mushrooming and/or the penetration and fragmentation of bone may add to the severity of the wound by providing additional projectiles which tear tissue along the wound track. Tissues which have been torn or crushed by this process fill with blood from the disrupted small blood vessels in the area. While this process represents the basic mechanism of gunshot wounding, the visual effects may vary somewhat depending on the type of tissue through which the bullet is traveling. Highly elastic tissue such as lung tissue may absorb the kinetic energy and crushing effects of a bullet in a manner very different from less elastic tissue such as bone, muscle or liver which may fracture or tear giving a more “pulverized” appearance.

On the other hand, a hunting arrow broad head cuts its way through tissue. While the mass of the arrow may be relatively large, the velocity of the arrow is slow compared to a bullet. Arrows do

not mushroom or fragment on impact so satellite projectiles are not produced. While bones may certainly be fractured by arrows, the transfer of velocity from the arrow to the bone fragments does not occur as in the case of a bullet. The arrow cuts its way through tissue leaving very limited tissue disruption other than cutting of tissue along the actual wound path. Hemorrhage from incised large vessels or organs such as the heart leads to death in a clean kill from a well placed arrow. The tissue surrounding the arrow wound track may be relatively bloodless if blood pressure is quickly decreased by an arrow penetration of the heart or

Richard K. Stroud DVM MS
Veterinary Medical Examiner
US Fish and Wildlife Service
National Wildlife Forensics
Laboratory

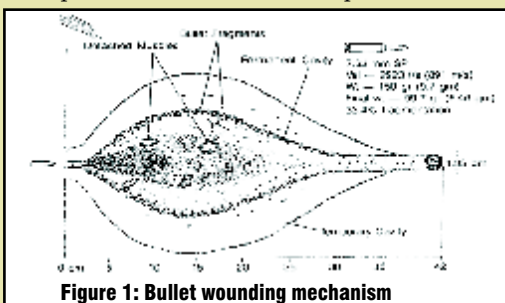
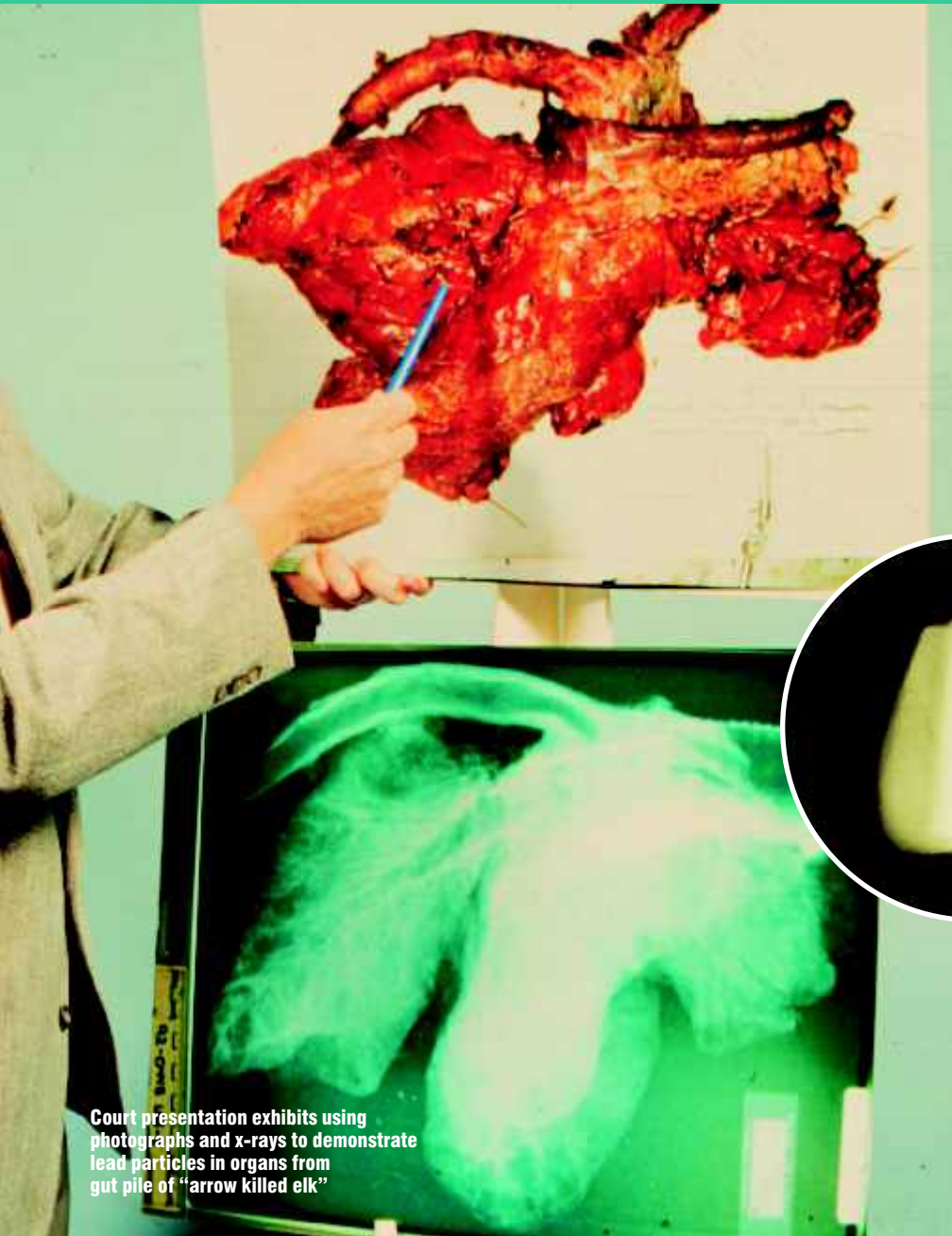

Figure 1: Bullet wounding mechanism



Court presentation exhibits using photographs and x-rays to demonstrate lead particles in organs from gut pile of "arrow killed elk"

determine if additional wounds are present. Wounds in the neck, brisket area (front of chest), or abdomen might also be further examined if they are claimed as the fatal arrow wound. A good ethical bow hunter will only take a good clear lateral chest shot to puncture the heart or lungs and bleed the animal out quickly. Shots to the neck, brisket or abdomen are unlikely to result in a clean kill. Check the trajectory of the wound path if possible. Arrow shots from tree stands may enter the dorsal aspect of the thorax and travel through the chest exiting ventrally. Both

entrance and exit wounds (if present) should be examined to determine if a clear path through vital organs is possible and that both are truly incised types of wounds. Modern bows normally drive an arrow completely through a deer or even an elk unless the arrow embeds in the spine or shoulder.

Arrows are more likely to be shoved into a bullet exit wound than an entrance wound because the exit wound is usually more obvious than an entrance wound in a heavily haired animal.

Figure 2: X-ray of fracture of deer scapula (shoulder blade) by arrow.

Wounds through the rib cage should be examined from the inside of the chest cavity. Does the wound through the chest have an incised edge with the pattern of a broad head or is there evidence of more extensive damage to the tissue surrounding the wound path? Arrows may fracture ribs and shoulder blades or even large leg bones. However, an arrow bone break is usually relatively clean and the wound channel does not contain small fragments of "granular" bone which are characteristic of bullet bone fractures (See Figure 2). Subcutaneous hemorrhage around the entrance wound may also be suspect if it is extensive. Arrows passing through the skin and into the underlying tissue should leave a stab wound with comparably little subcutaneous hemorrhage. A high velocity bullet passing through the skin may cause significant tearing of subcutaneous tissue with extensive blood infiltration (See Figure 3).

aorta which is the main target of a good archer. However, a completely bloodless wound, even though it may be an obvious incised wound, may be a post mortem attempt to simulate an archery kill and should be more closely examined.

Examining the Evidence

The field investigator may encounter evidence in a variety of forms ranging from intact carcasses to pieces of skin or tissue. The examination of an intact or field dressed carcass is of course much easier to evaluate accurately than a caped out or skinned big game animal and a freezer full of meat.

Intact or Field Dressed Carcass

As they say in real estate, location, location, location! If you have a full carcass to examine, is the wound location consistent with a good killing arrow shot through the chest? Are other wounds present in the carcass that perhaps suggest that the animal was shot and then finished off with an arrow placed in the chest? Small caliber bullet wounds in the neck or head are easy to miss in a deer carcass but may be the cause of death or debilitation in an illegal kill. Skinning or x-rays of the neck and head may be necessary to

Carcasses of large game animals with wounds which fracture vertebra that are claimed as archery kills are also suspect. Today's arrows, even with chisel points, do not have the capability to shatter the spine of a deer or elk like a bullet. An arrow may penetrate the spinal channel and sever the spinal chord but the capability to fracture the base of the vertebra with an arrow is improbable.

Skin, Parts and Gut Piles

When the carcass is disassembled, documentation of a cause of death due to legal archery kill may be more difficult to ascertain. The problem comes with ruling out gunshot wounds in parts that are missing or altered. However, available wound tissue may be collected and examined.

The cape or skin is a good place to start as this is often available, especially in a trophy animal. Examine the characteristics of the hole in the skin. Does the hole conform to the expected characteristic cutting edges of a three or four bladed arrow head? Remember that an arrow entering the skin at an angle may give a pattern different from a straight perpendicular entrance. Does the hole represent an entrance or an exit wound? An entrance wound of an arrow should have at least some hairs that over lay the wound cut off evenly along the same plane as the skin incision (See Figure 4). A post

mortem arrow wound made by someone pushing an arrow into a carcass or into a pre-existing bullet wound may not cut the over laying hair in an even manner because the hairs are "pushed aside" opposed to having been cut cleanly by the fast moving arrow blade. An arrow exit wound, with the cutting edges of the arrow head emerging from the flesh side of the skin, is not likely to cut hairs over laying the wound. Hemorrhage along the wound edges and blood caked in the hair around the wound is a good indication that the wound was indeed a pre-mortem wound (see Figure 5).

Wounds in the skin that are suspect bullet wounds should be collected, protected from contamination and further examined in a forensic laboratory. As a bullet penetrates the skin, it starts to mushroom or destabilize and tumble through the underlying tissue layers. In an illegal kill, it is likely that the blood shot wound tissue has been trimmed from the carcass and may or may not be available for analysis.

However, if a bullet made the original wound, at either the entrance or the exit point on the skin, a bullet wipe and/or particulate from the bullet may still be available in the edges of the wound (See Figure 6). Generally speaking, because of the expansion and fragmentation of the bullet, tissues around a suspected exit wound are more productive of metallic particles from a bullet than skin tissues around an entrance wound (See Figure 7).

Some have advocated the use of sodium rhodizonate based field chemical tests for lead in the tissue. These tests have limited accuracy and will give a reported 50% false negative result. X-rays taken of the wound tissue is a more accurate way to demonstrate the presence of lead or copper particles. It is advisable to collect the particles identified by the x-ray from the skin and have them chemically analyzed to prove they are indeed lead or copper consistent with a bullet.

This may be a very difficult task and the particles may be very small. If all else fails, the wound tissue itself may be chemically analyzed for excess lead residue. The investigator must provide one or more tissue samples from the same animal from an area completely away from the suspected wound to be used as negative controls for the analysis. Studies done to date show that hunting arrow points

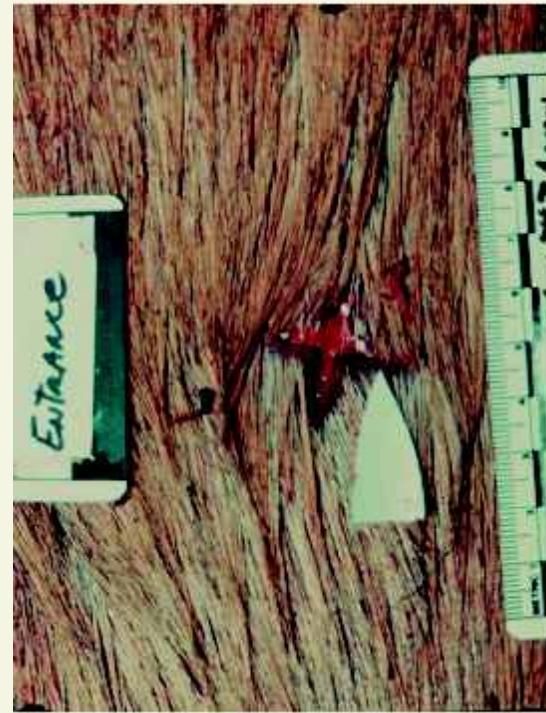

Figure 4: Cut hairs over arrow entrance wound

do not leave lead or copper residue in the tissue through which they pass. Certain bullets such as solid copper bullets or full metal jacket military type bullets also leave no lead residue in the wound track.

A skin which has not had the subcutaneous tissue removed (flensing) is more likely to contain bullet particles than either a flensed skin or a tanned hide. An x-ray of the skin should demonstrate a pattern of radio dense particles around the hole rather than randomly scattered radio dense particles on the skin. Skinning of an animal in a garage or other location where welding, metal grinding or other such work has been done may lead to the presence of metallic particles which contaminate the skin. These may have a different chemical composition than bullet lead or copper. Laboratory chemical analysis will validate the character of the suspect particles. Even in cases where no particles are visualized on x-rays, an examination using an XRF (X-ray Refractive Fluoresce Spectrophotometry) may demonstrate copper or lead contamination around the inside rim of the hole through the skin. Many forensic laboratories have an XRF as standard instrumentation for forensic investigation of evidence.

If the kill or butcher site is located, wound tissue from the gut pile or wound trimming should be collected and examined. Radiographs may demonstrate the presence of radio dense metallic particles in the material available. X-rays showing metallic particles make excellent courtroom displays because they are very visual (see figure 8).



Communications training designed specifically for the game warden

Forensic Interview & Interrogation Techniques for Conservation Officers

Jeffrey N. Baile & Associates

- ✓ Body language analysis
- ✓ Rapport building and conflict resolution
- ✓ Truth and lie simulations
- ✓ Game warden interrogation methods
- ✓ False confession discussion
- ✓ Microfacial expressions test
- ✓ Courses are tailored to individual agency needs
- ✓ Flat rates
- ✓ No class size restrictions
- ✓ Recruit Course - up to 4 days
- ✓ Field Officer Course - 3 days
- ✓ Follow-up 2-day Practical Interrogation course available



For a free information packet contact:

Jeffrey N. Baile & Associates
3408 West Chartwell Rd., Peoria, IL 61614
PH: 309.692.3251 Email: jbaile@insightbb.com

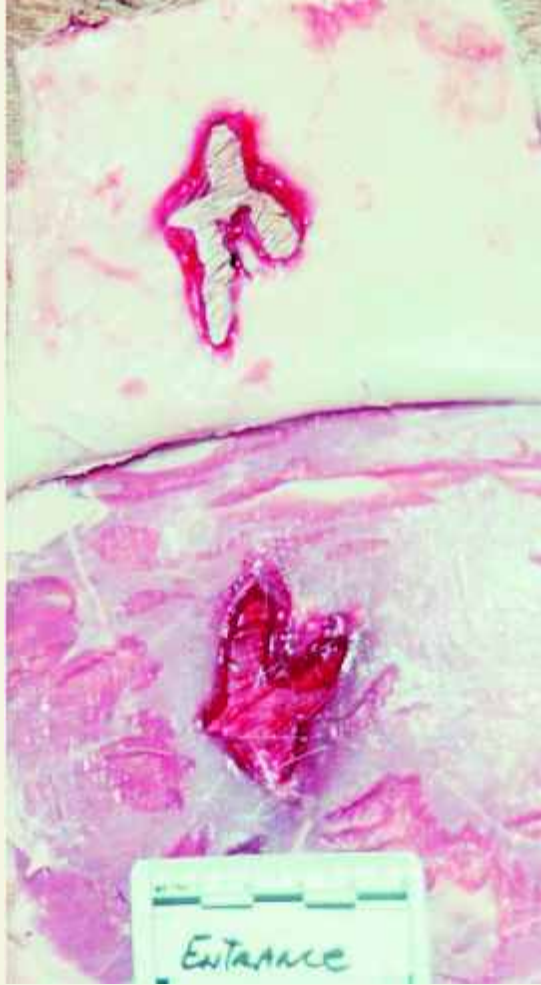


Figure 5: Hemorrhage along edges of premortem arrow wound.

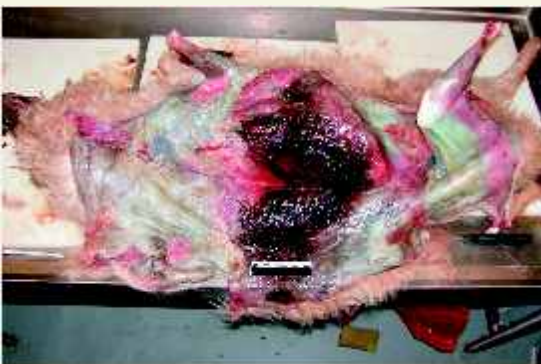

Figure 3: Massive subcutaneous hemorrhage around bullet entrance wound

Preparing for the Defense

“Gunshot” archery kills, in my experience, usually involve the taking of trophy animals. These cases may be defended vigorously because of the high ego factor of trophy hunters and the high dollar value of such trophies. One such case that I participated in was appealed twice in local and district courts and finally dismissed on a third appeal to a state supreme court. Therefore, proper collection, documentation of chain of custody, care and preservation of evidence in the field as well as the proper description of examination findings is

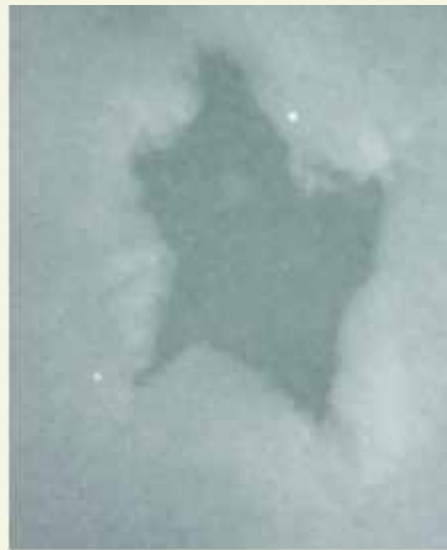
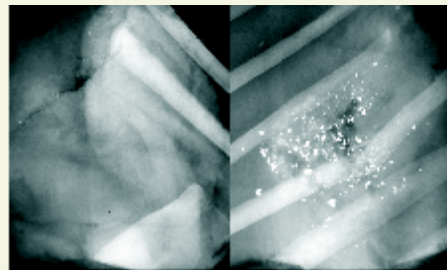


Figure 6: X-ray of lead particles on edges of “arrow wound”.



**Figure 7, left: x-ray of entrance wound
Figure 8, right: exit wound of a high velocity bullet**

essential. Good forensic quality photographs and x-rays are invaluable in providing credible testimony in court so take twice as many photos as you think you need, include various angles of the lesion or carcass and place rulers and identification numbers in the photographs for reference. If you involve your local veterinarian to take x-rays or to evaluate wound tissue, be sure to have him follow standard legal evidence handling and documentation protocols.

Building the case starts with proving that the suspected fatal wound was originally made by a bullet. The presence of a bullet or bullet fragments may prove that the wound was indeed made by a bullet, even if an arrow was shoved into the wound post mortem. The next step is proving that the wound in question was the fatal wound. The third step is to disprove that the animal was not previously wounded by persons unknown prior to the defendant legally taking the trophy with approved archery methods. An astute defense lawyer will question the duration and the lethality of the “bullet” wound. The advantage of examining the whole carcass, including the guts left at the kill site, is obvious in explaining the lethality of a wound. An

elk with its heart or lungs blown out and full of metallic particles from a bullet is not likely to be bugling and chasing cows when the defendant “arrowed” him with a good shot into the chest, even if the defendant thought he heard a gunshot earlier in the morning.

If the wound is claimed as a previous non fatal bullet wound by the defense, evidence of the presence or absence of tissue reaction or healing may provide insight into the duration of the wound. Histopathological evaluation of the tissue of the wound may be required to actually prove that the wound is fresh having been made at or near the time of death. The tissues for histological examination by a pathologist must be fixed in 10 % formalin and prepared for microscopic examination in order to document the absence or presence of cellular changes. If such a defense is anticipated, the actual “bullet” hole with the surrounding tissue may be collected and fixed in formalin instead of frozen. Be sure to adequately document the location of the wound tissue sample taken from the skin with photographs. Include a ruler in the photo to document size as well as identifying case number information.

Making the Case

Generally speaking, archery hunters, as a group, are the finest hunters and sportsmen around. The taking of a big game animal with a bow is far more of a challenge than taking it with a gun. Patience and skill, which comes with hours of practice, define the archery hunter who is serious about his sport. Most of the archery seasons are set to give the archer a chance to take a trophy animal without having to compete with rifle hunters. Unfortunately, there are those who wish to cheat and take unfair advantage of the situation by using a firearm during archery season. Most serious archery hunters are more than happy to assist in preventing this illegal type of take which robs them of their right to take a trophy animal under “fair chase”.

The key to making such cases is careful collection and documentation of the evidence which may speak for itself once shown to a judge or jury. Pictures and hard forensic evidence that can be used to tell the story have a high value in a court of law, if the case gets that far. A professional thorough investigation with proper documentation and evidence collection may also send a message to the suspect that the “game is up” and it only gets worse from here! 🦌